

J Antimicrob Chemother 2013

doi:10.1093/jac/dks435

Advance Access publication 30 October 2012

Altered antibiotic pharmacokinetics during extracorporeal membrane oxygenation: cause for concern?

Kiran Shekar^{1*}, Jason A. Roberts², Sussan Ghassabian³, Daniel V. Mullany¹, Steven C. Wallis², Maree T. Smith³ and John F. Fraser¹

¹Critical Care Research Group, Adult Intensive Care Services, The Prince Charles Hospital, The University of Queensland, Queensland, Australia; ²Burns Trauma and Critical Care Research Centre, The University of Queensland, Queensland, Australia; ³Centre for Integrated Preclinical Drug Development, The University of Queensland, Queensland, Australia

*Corresponding author. Tel: +617-3139-4000; Fax: +617-3139-6120; E-mail kiran_shekar@health.qld.gov.au

Keywords: ICU, renal replacement therapy, therapeutic drug monitoring, toxicity, treatment failure

Sir,

Extracorporeal membrane oxygenation (ECMO) is a supportive therapy and definitive management often relies on adequate drug therapy aimed at reversing the underlying cause of cardiac and/or respiratory failure. Despite this, a paucity of data exists describing the impact of ECMO on pharmacokinetics (PK) and antibiotic dosing requirements. By default, clinicians prescribe standard doses to these complicated patients, thereby risking therapeutic failure or toxicity. We report two patients to highlight our concerns with regard to antibiotic therapy in the presence of ECMO. Ethics approval was granted by the local Human Research Ethics Committee (HREC/11/QPCH/121).

The first patient with pneumonia and respiratory failure was supported with venovenous ECMO. Meropenem (1 g every 8 h) was commenced for *Enterobacter* septicaemia. Serial blood samples (2 mL) were collected to assay meropenem plasma concentrations (Figure 1). The meropenem clearance (CL) was 20.4 L/h, which is higher than that for critically ill patients either without renal dysfunction (13.6 L/h) or those with renal failure receiving high-volume continuous venovenous haemofiltration (6.0 L/h).^{1,2} The calculated volume of distribution (V) was also high at 0.56 L/kg.² Whilst a minimum target of 40% for the time that the meropenem concentration was maintained above the MIC (40% $T_{>MIC}$) was achieved, the more aggressive target (4× MIC that is used clinically, 8 mg/L) was only achieved for 30% of the dosing interval.

The second patient received venoarterial ECMO and extended daily diafiltration (EDD-f) for *Pseudomonas aeruginosa* pneumonia and multiorgan failure. Guided by the data from Patient 1, meropenem was administered as a high-dose infusion (6.5 g every 24 h) and serial blood samples (2 mL) were collected for measurement of meropenem plasma concentrations (Figure 1). The meropenem CL was once again high at 20.8 L/h. However, this elevated dosing regimen successfully maintained

meropenem plasma concentrations above the target level (4× MIC, where the *P. aeruginosa* MIC is 2 mg/L).³

The ECMO circuitry in both patients comprised bioline tubing, a centrifugal pump and a polymethyl pentene oxygenator (pump, Jostra Rotaflow™ and oxygenator, Quadrox D™; Maquet, Germany). Dosing meropenem as per standard practice resulted in underdosing in the first patient with isolated respiratory failure. A higher dose administered by continuous infusion was necessary to maintain optimal meropenem concentrations in the second patient with multiple organ failure, who received EDD-f. Both patients demonstrated a high meropenem CL despite significant differences in their severity-of-illness sequential organ failure assessment score of 4 versus 17 on the day of PK sampling.

The meropenem CL seen in these two patients was substantially higher than is seen in critically ill patients not on ECMO^{1,2} and may be due in part to circuit sequestration. A recent *ex vivo* study demonstrated significant sequestration of meropenem in adult ECMO circuits.⁴ On the contrary, Wildschut *et al.*,⁵ in their *in vitro* study using neonatal circuits, demonstrated no significant meropenem loss in the circuit beyond 60 min. However, it should be noted that meropenem is unstable at 37°C and ongoing exteriorization of blood during ECMO may lead to a degree of spontaneous degradation, which can be erroneously interpreted as increased CL. Whether there is saturation of the circuit over time for meropenem remains to be determined in future studies. Although there are no meropenem CL data in neonates on ECMO for comparison, it is likely to be low given the organ immaturity and physiological differences.⁶ Studies in neonates on ECMO have consistently shown reduced CL for several antibiotics.⁷

Factors affecting PK during ECMO include sequestration in the circuit, increased V and decreased CL.⁷ Most of the available PK data are from neonates and relate to sedative and antibiotic drugs. Emerging data from adult patients on ECMO suggest escalating sedation requirements over time.⁸ However, unlike sedation, there are no real-time pharmacodynamic endpoints for

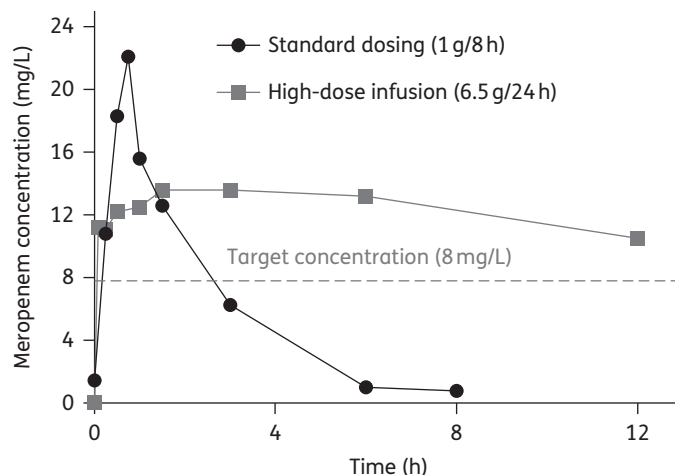


Figure 1. Effects of two dosing regimens on plasma meropenem concentrations in adult patients receiving ECMO. Meropenem concentrations at time 0 relate to the baseline levels prior to administration of the drug.

antibiotic therapy and therapeutic drug monitoring is available for only a handful of antibiotics. This is important, as suboptimal antibiotic therapy is associated with worse outcomes.⁹ Systematic research using *ex vivo* circuits, large animal models¹⁰ and population PK studies are indicated to improve antibiotic prescription and, hence, patient outcomes during ECMO.

Acknowledgements

We thank Ms Rachel Buschel for assistance with data collection and Dr Marc Ziegenfuss, Director, Adult Intensive Care Services, The Prince Charles Hospital, for facilitating the study.

Funding

This work was supported in part by funding provided by the Australian and New Zealand College of Anaesthetists, the Intensive Care Foundation and the Prince Charles Hospital Foundation. J. A. R. is funded by a National Health and Medical Research Council Australian Research Training Fellowship (409931). J. F. F. currently holds a Health Research Fellowship awarded by the Office of Health and Medical Research, Queensland, Australia.

Transparency declarations

None to declare.

References

- Roberts JA, Kirkpatrick CM, Roberts MS *et al.* Meropenem dosing in critically ill patients with sepsis and without renal dysfunction: intermittent bolus versus continuous administration? Monte Carlo dosing simulations and subcutaneous tissue distribution. *J Antimicrob Chemother* 2009; **64**: 142–50.
- Bilgrami I, Roberts JA, Wallis SC *et al.* Meropenem dosing in critically ill patients with sepsis receiving high-volume continuous venovenous hemofiltration. *Antimicrob Agents Chemother* 2010; **54**: 2974–8.
- Roberts JA, Ulldemolins M, Roberts MS *et al.* Therapeutic drug monitoring of β -lactams in critically ill patients: proof of concept. *Int J Antimicrob Agents* 2010; **36**: 332–9.
- Shekar K, Roberts JA, McDonald CI *et al.* Sequestration of drugs in the circuit may lead to therapeutic failure during extracorporeal membrane oxygenation. *Crit Care* 2012; **16**: R194.
- Wildschut ED, Ahsman MJ, Allegaert K *et al.* Determinants of drug absorption in different ECMO circuits. *Intensive Care Med* 2010; **36**: 2109–16.
- Alcorn J, McNamara PJ. Pharmacokinetics in the newborn. *Adv Drug Deliv Rev* 2003; **55**: 667–86.
- Shekar K, Fraser JF, Smith MT *et al.* Pharmacokinetic changes in patients receiving extracorporeal membrane oxygenation. *J Crit Care* 2012; doi:10.1016/j.jcrrc.2012.02.013.
- Shekar K, Mullany DV, Corley A *et al.* Increased sedation requirements in patients receiving extracorporeal membrane oxygenation for respiratory and cardio-respiratory failure. *Anaesth Intensive Care* 2012; **40**: 648–55.
- Kollef MH, Sherman G, Ward S *et al.* Inadequate antimicrobial treatment of infections: a risk factor for hospital mortality among critically ill patients. *Chest* 1999; **115**: 462–74.

- Shekar K, Fung YL, Diab S *et al.* Development of simulated and ovine models of extracorporeal life support to improve understanding of circuit–host interactions. *Crit Care Resusc* 2012; **14**: 105–11.

J Antimicrob Chemother 2013

doi:10.1093/jac/dks433

Advance Access publication 1 November 2012

Sialolithiasis in an HIV-1-infected patient treated with atazanavir/ritonavir monotherapy

Minh P. Lê^{1*}, Hind Stitou², Cathia Soulie³,
Christine Katlama² and Gilles Peytavin¹

¹APHP, Bichat-Claude Bernard Hospital, Clinical Pharmacokinetic Department, EA4409 Paris 7 University, Paris, France; ²APHP, La Pitié-Salpêtrière Hospital, Infectious Diseases Department, U943 Université Paris 6 Pierre et Marie Curie, Paris, France; ³APHP, La Pitié-Salpêtrière Hospital, Virology Department, U943 Université Paris 6 Pierre et Marie Curie, Paris, France

*Corresponding author. Clinical Pharmacokinetic Department, Bichat-Claude Bernard Hospital, 75018 Paris, AP-HP, France. Tel: +33-1-40-25-84-54; Fax: +33-1-42-63-58-25; E-mail: le.minhpatrick@gmail.com

Keywords: antiviral therapy, protease inhibitor, adverse reactions, salivary, parotid, calculus

Sir,

An adult Caucasian HIV-infected male attended the infectious diseases department of Pitié-Salpêtrière Hospital in February 2012 for a painful submandibular tumefaction.

His medical history presented several notable events: HIV infection (diagnosed in 1986); a chronic hepatitis C with a genotype 1 virus diagnosed in 1993 and cured after pegylated interferon and ribavirin therapy in 2004; and sialolithiasis that occurred in 2009 without stone examination at that time. Occasional use of alcohol, tobacco and cannabis was noted in his file.

His CD4 count nadir was 204 cells/mm³ and antiretroviral treatment was initiated in 1991. At no time did he present any AIDS-related event, but he experienced several antiretroviral combinations (lamivudine, zidovudine, stavudine, didanosine, abacavir, nevirapine, indinavir/ritonavir and lopinavir/ritonavir) because of persistent plasma HIV-RNA after poor tolerance and adherence difficulties. A regimen combining atazanavir/ritonavir + tenofovir/emtricitabine was initiated in 2006, and plasma HIV-RNA <50 copies/mL and CD4 counts >600 cells/mm³ were obtained. Simplification to atazanavir/ritonavir (300/100 mg, once daily) monotherapy was undertaken in March 2011.

The cervical tumefaction comprised an infection of the left submandibular gland with a blocked parotid duct. The ultrasound examination revealed a size-increased submandibular gland (52×30 mm) and a parotid duct dilated (8 mm internal diameter) by the presence of four calculi (3.4, 4.2, 5.8 and